

CASE STUDY

- 100% WOUND HEALING IN 16 WEEKS
- 15 ACTIGRAFT APPLICATION

PATIENT:

79 Year Old, Male

PAST MEDICAL HISTORY:

Diabetes Mellitus Type II, HTN, high cholesterol, skin sensitivity

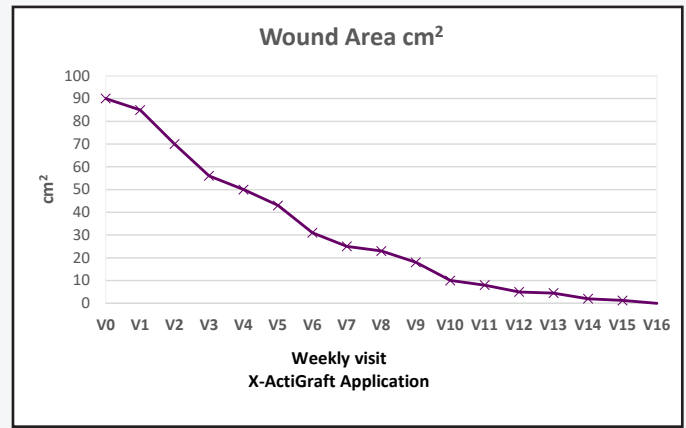
WOUND HISTORY:

- N/A

PAST TREATMENTS:

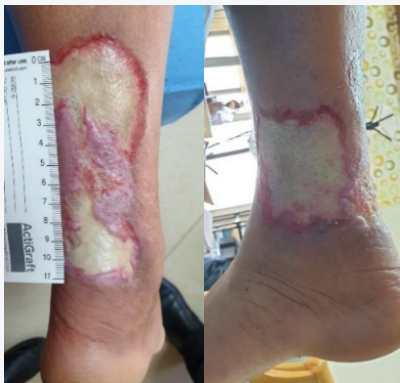Topical antiseptic ointments, debridement, Ozone therapy, NPWT

ACTIGRAFT TREATMENT PROGRESSION:



V=Weekly Application

Day 1



Week 16

